



## COVID-19 presenting as intussusception in infants: A case report with literature review

Mohammad N. Athamnah<sup>a,\*</sup>, Salim Masade<sup>b</sup>, Hanady Hamdallah<sup>c</sup>, Nasser Banikhaled<sup>d</sup>, Wafa Shatnawi<sup>e</sup>, Marwa Elmughrabi<sup>f</sup>, Hussein S.O. Al Azzam<sup>a</sup>

<sup>a</sup> General Surgery Department, Princess Basma Teaching Hospital, Jordan Ministry of Health, Irbid, Jordan

<sup>b</sup> Jordanian Royal Medical Services, Jordan

<sup>c</sup> Chester Medical School, University of Chester, United Kingdom

<sup>d</sup> Pediatric Infectious Diseases, Jordanian Royal Medical Services, Jordan

<sup>e</sup> Family Medicine, Jordan Ministry of Health, Jordan

<sup>f</sup> Private Sector, Irbid, Jordan

### ARTICLE INFO

#### Keywords:

COVID-19

Intussusception

Mesenteric lymphoid hyperplasia

Infants

### ABSTRACT

The novel Corona virus disease 2019 (COVID-19) first presented in Wuhan, China. The virus was able to spread throughout the world, causing a global health crisis. The virus spread widely in Jordan after a wedding party held in northern Jordan. In most cases of COVID-19 infection, respiratory symptoms are predominant. However, in rare cases the disease may present with non-respiratory symptoms. The presentation of COVID-19 as a case of intussusception in children is a strange and rare phenomenon. We present here a case of a two-and-a-half month old male baby who was brought to hospital due to fever, frequent vomiting, dehydration and blood in stool. He was diagnosed as intussusception. The child was tested for corona due to the large societal spread of the virus and because he was near his mother, who was suffering from symptoms similar to corona or seasonal flu (she did not conduct a corona test). Patient was treated without surgery and recovered quickly. The COVID-19 infection was without respiratory symptoms, and there was no need for the child to remain in hospital after treatment of intussusception. The relationship between viruses, mesenteric lymphoid hyperplasia, and intussusception is a confirmed relation. ACE2 is the key receptor required for SARA-COV-2 to enter the host cells. ACE2 has been also found in the brush border of the intestinal mucosa, as well as it is a key inflammatory regulator in the intestine. This may suggest that SARS-COV-2 could invade the respiratory tract as well as gastrointestinal tract or both. Few case reports documented the presentation of COVID-19 as intussusception in children. In the light of the wide-spread of corona virus, performing COVID-19 tests for children with intussusception can help linking the two entities. Development of gastrointestinal symptoms in COVID-19 positive children should raise concern about the development of intussusception.

### 1. Introduction

Late 2019, in Wuhan, China, patients who presented with dry cough, decreased or normal white blood cells and fever were diagnosed as “Fever of Unknown Origin with pneumonia” [1]. Soon after that, the causative agent for this “Fever of Unknown Origin with pneumonia” was attributed to the novel severe acute respiratory syndrome corona virus 2 (SARS-CoV-2), i.e. Corona virus disease 2019 (COVID-19) [2]. Corona Virus has strong Human to human transmission and can lead to serious

respiratory complications that may cause death [3]. In few months after the detection of the first Wuhan COVID-19 case, the novel virus was able to spread further internationally and became a global concern and emergency [2]. By March 12th, 2020 Jordan had only one confirmed case of COVID-19 [4], but a wedding ceremony in northern Jordan led to the infection of 76 patients [5]. In April 10th, 372 cases were confirmed in Jordan, around quarter of which are related to the above-mentioned wedding ceremony [6]. Disease spread continued to take place in Jordan in spite of the multiple partial and complete lockdowns. Different cities

\* Corresponding author.

E-mail addresses: [Mathamneh85@gmail.com](mailto:Mathamneh85@gmail.com) (M.N. Athamnah), [Salimmasadeh@gmail.com](mailto:Salimmasadeh@gmail.com) (S. Masade), [h.hamdallah@chester.ac.uk](mailto:h.hamdallah@chester.ac.uk) (H. Hamdallah), [hawimahdianzi@gmail.com](mailto:hawimahdianzi@gmail.com) (N. Banikhaled), [wafashatnawi@gmail.com](mailto:wafashatnawi@gmail.com) (W. Shatnawi), [Melmughrabi985@gmail.com](mailto:Melmughrabi985@gmail.com) (M. Elmughrabi), [hussainalazzam@yahoo.com](mailto:hussainalazzam@yahoo.com) (H.S.O. Al Azzam).

<https://doi.org/10.1016/j.epsc.2021.101779>

Received 23 December 2020; Accepted 31 December 2020

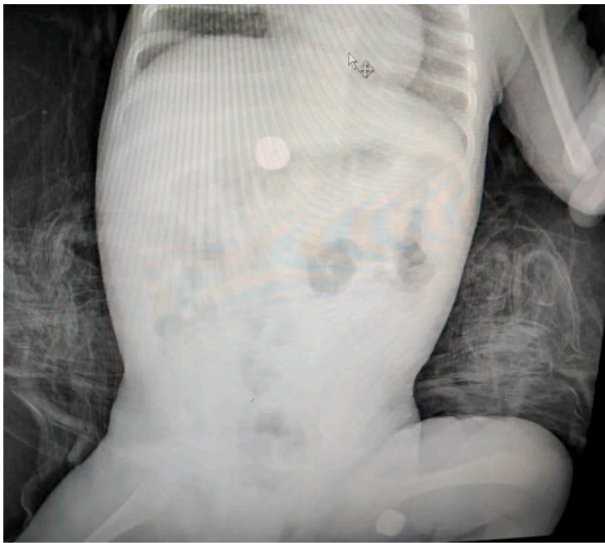
Available online 7 January 2021

2213-5766/© 2021 The Author(s).

Published by Elsevier Inc.

This is an open access article under the CC BY-NC-ND license

(<http://creativecommons.org/licenses/by-nc-nd/4.0/>).



**Fig. 1.** Abdominal X-ray showing normal gas distribution after pneumatic reduction.

and areas were isolated from the rest of the country according to their epidemiological situation in an attempt to control the disease. By 22nd of November 2020, Jordan reached wide spread community transmission status recording more than 178 thousand cases of COVID-19 [7]. COVID-19 usually presents with respiratory symptoms and other common symptoms including cough, fever, dyspnoea, musculoskeletal symptoms (myalgia, joint pain, fatigue), gastrointestinal symptoms, and anosmia/dysgeusia [8]. The presentation of COVID-19 as intussusception is very rare. A review of the literature and a case reporting confirmed positive COVID-19 infant in Jordan who presented as intussusception will be discussed here.

## 2. Case presentation

A 10-week-old male infant, normal vaginal delivery after full term pregnancy (39 weeks), with no history of Neonate intensive care unit admission. Transferred from peripheral hospital complaining of vomiting, abdominal distension. Upon arrival the baby was looking ill, febrile 38.5 °C, poor feeding, heart rate was 130 beats per minute with an oxygen saturation of 97%, and the baby had a recurrent attack of bouts of crampy abdominal pain.

Signs of dehydration were noted upon physical examination. Ear, nose, throat examination showed unremarkable changes. Similarly, chest examination showed good air entry with no significant finding. Abdominal examination showed diffuse central tenderness along with bilious discharge from the Naso-Gastric tube NGT. Rectal exam showed jelly like material mixed with soft stool. Importantly, the mother reported that she had a flu-like symptoms 10 days ago. However, she is symptoms free as her symptoms subsided 3 days ago. Complete blood count, Chest X-Ray and abdominal X ray beside abdominal ultrasound were requested for the baby. White blood count was normal along with Chest X-Ray. Abdominal x-ray showed evidence of distal small bowel obstruction and decreased gas in the colon. Abdominal ultrasound revealed evidence of ilioocolic intussusception (Target sign) . Accordingly, PCR was requested together with I.V fluid and antibiotics (Cef-tazidime 35 mg/Kg and metronidazole 15 mg/Kg). Non-surgical (Pneumatic) reduction of intussuscepted bowel (ileocolic intussusception) was performed under guidance after insufflation of air at 120 mm Hg for 2 minutes as recommended for the treatment of stable intussusception patients [9]. Free flow of air was observed in the large and small intestine, representing a successful reduction of intussusception. Fig. 1. Four hours later the COVID-19 PCR test was reported as positive.

After intussusception reduction, patient improved dramatically, there was no need for further treatment of COVID-19; Patient was discharged the next day after reduction and parents were advised to follow isolation protocols and return back for regular clinic visit or in case new symptoms develop.

## 3. Discussion

Most COVID-19 patients present with respiratory symptoms, few of them presents with non-respiratory complaints [10]. The gastrointestinal symptoms of COVID-19 in children are usually limited to abdominal pain, diarrhoea and vomiting [11]. Intussusception is the leading cause of gastrointestinal obstruction in young children [12]. The presentation of COVID-19 as intussusception is only documented in four cases before this case report [10,13–15]. Mesenteric lymphoid hyperplasia seems to be the main reason and key pathophysiology of intussusception in children [16]. There is a very strong casual association between Viruses, Mesenteric lymphoid hyperplasia and intussusception [17]. Geographic and environmental factors play important role in intussusception incidence rate. The incidence of intussusception varies among different countries, for example, incidence of intussusception is four times higher in Vietnam than Australia [18]. Viral infections have a strong relation with intussusception, but the relationship between intussusception and COVID-19 is an insufficiently studied topic; mainly because COVID-19 is an emerging virus and more cases and tests are required to link between the two entities.

ACE2 is the key receptor required for SARS-COV-2 to enter the host cells [19], where SARS-COV-2 adhere to the host cell membrane via glycoprotein S (Spike) which separated by Furin and transmembrane serine proteases enzyme (TMPRSS2) in to S1 and S2 [20]. Then, the virus enter the host cell by endocytoses when S1 binds with ACE2 and S2 bind to the cell membrane [20,21]. The evidence suggests that both ACE2 and TMRSS2 is expressed in lung alveolar type A2 as well as in the oesophagus upper and stratified epithelial cells and absorptive enterocytes from ileum and colon [20]. ACE2 has been also found in the brush border of the intestinal mucosa [22], as well as it is a key inflammatory regulator in the intestine [23]. This may suggest that SARS-COV-2 could invade the respiratory tract as well as gastrointestinal tract or both, but it is not clear which one take place first. This suggestion aligned with the finding of Xu et al. (2020) [24] who reported that 8 out of 10 children tested positive for SARS-COV-2 test were tested positive for a rectal swabs, and it also support the proposed faecal-oral transmission as a possible rout to spread the infection which has been discussed in multiple reviews [20,21,25,26]. Perhaps considering stool and rectal swabs together with oropharyngeal swabs in the future paediatric cases with GIT symptoms would help to get a better explanation about faecal-oral transmission of SARS-COV-2. Also rectal swabs and oropharyngeal swabs for SARS-COV-2 in intussusception patients will help confirming the relation between SARS-COV-2 and intussusception.

The mechanism behind the development of the intussusception in paediatric with SARS-COV-2 is not fully understood, and generally, it could be idiopathic [15]. Intussusception is associated with multiple viral infections such as, respiratory adenovirus [27], rota viruses [28] and Interestingly, it has been reported previously in a male short-haired Chihuahua infected with canine coronavirus [29] which might suggest a link between the Corona virus and the development of intussusception in mammals.

SARS-COV-2 could be presented with sever inflammatory condition known as cytokines storm, which is mainly originated from respiratory tract, but the exclusive presence of gastrointestinal symptoms with the absence of respiratory symptoms in several positively tested adults [30] and children [13,31] might suggest that the cytokines storm could be originated from the Gastro intestinal tract (GIT) causing GIT symptoms and complications including intussusception, where a significant association was found between acute intussusception in paediatric and

**Table 1**  
Showing cases retrieved from literature reporting intussusception in positive COVID-19 infants.

	Athamnah et al.	Moazzam et al. [13]	Cai et al. [10]	Bazuaye-Ekwuyasi et al. [14]	Martinez-Castano et al. [15]
Age (months)	2.5	5	10	9	6
Gender	MALE	MALE	FEMALE	MALE	MALE
Direct COVID-19 exposure	YES (from mother)	NONE	NONE	Yes (from relatives)	Yes (from relatives)
Fever at presentation	38C	Afibrile	39.8 °C	38.2 °C	Afibrile
Presentation	Typical intussusception manifestation	Episodic abdominal pain, with currant jelly stools	Recurrent vomiting, currant jelly stool	Episodic abdominal pain, with dark stools	Recurrent vomiting, currant jelly stool
Treatment	Pneumatic Reduction	Pneumatic Reduction	Pneumatic Reduction then surgery	Hydrostatic Reduction	Hydrostatic Reduction
Outcome	Discharged in good health	Discharged in good health	Died	Discharged in good health	Discharged in good health

high-level of circulating inflammatory cytokines and plasma CRP [32]. This hypothesis could be explained by the fact that the intestine has large number of mesenteric lymph nodes and Peyer patches, activated T cells, mast cells, plasma cells and macrophages, and during infection lymphadenopathy and hypertrophy of Peyer patches is taking places causing intussusception [20]. The presence of intussusception in SARA-COV-2 could be explained by the previously reported association between the viral infection and the delay in the peristaltic movement of the gut which leading to telescoping of the adjacent loops of bowel into each other causing intussusception [19].

To the best of our knowledge, four cases before reported intussusception as the presentation of COVID-19 in children [10,13–15]. Cases presented as irritable baby with current jelly-like stool and fever. Reduction was performed in all cases. Pneumatic Reduction was not sufficient in Cai et al. [10], patient needed exploration laparotomy with resection and anastomosis of necrotic small intestine and he was later diagnosed with multi-organ-failure and died after 36 days of admission. Patient in Moazzam et al. [13] recovered well and was discharged 7 days after reduction. The case reported in Cai et al. [10] was admitted early 2020 in Wuhan Children's Hospital. It was at the very beginning of an inadequately studied outbreak of unknown disease. This case was treated when the world was still surprised and shocked and standing bewildered in front of this new virus in terms of the virulence of the virus and the speed of its spread and transmission. The presentation of the disease in an unconventional way will definitely affect the results of the treatment, here lies the importance of documenting and studying these non-traditional manifestations of the virus in order to avoid delay in diagnosis, which will result in a delay in treatment and inferior outcomes. Table 1 compares the four documented cases of intussusception presentations associated with Covid-19 in children. Bazuaye-Ekwuyasi et al. [14] and Martinez-Castano et al. [15] both presented male babies with typical abdominal symptoms of intussusception and a history of COVID-19 exposure. Both babies were treated with Hydrostatic Reduction leading to full recovery.

Linking between Corona virus and intestinal intussusception and establishing the relationship between them may help avoid delays in diagnosis. Importantly, the development of symptoms related to the gastrointestinal system in children with corona should raise suspicion and make treating physicians directly think about the diagnosis of intussusception.

#### 4. Conclusion

The novel COVID-19 presents usually with respiratory symptoms. Unconventional presentations of this disease can include gastrointestinal symptoms. COVID-19 affecting infants and presenting as intussusception is rare. Only four case reports before this report documented this presentation. Performing COVID-19 rectal swabs beside oropharyngeal swabs for intussusception patients can help in understanding and determining the relation between intussusception and COVID-19. The development of symptoms related to the gastrointestinal system,

such as vomiting, constipation, blood in the stool, or abdominal distension in children with COVID-19 should lead doctors to suspect intussusception as a possible cause of these symptoms.

#### Patient consent

Consent to publish the case report was not obtained. This report does not contain any personal information that could lead to the identification of the patient.

#### Ethical approval

Case report need no ethical approvals.

#### Funding

No funding or grant support.

#### Authorship

All authors attest that they meet the current ICMJE criteria for Authorship.

#### Author contribution

Mohammad N. Athamnah, MD: First author and project manager.  
Salim Masade MD: Case documentation and Images and surgical team.  
Hanady Hamdallah: Literature Review.  
Nasser Banikhaled: Case documentation and infectious disease team.  
Wafa Shatnawi MD: Literature review.  
Marwa Elmughrabi MD: Literature Review.  
Hussein S O Al Azzam: Manuscript editing and proofreading.

#### Research registration Unique Identifying number (UIN)

- 1 Name of the registry:
- 2 Unique Identifying number or registration ID:
- 3 Hyperlink to your specific registration (must be publicly accessible and will be checked):

#### Guarantor

Mohammad Naser Athamnah, MD.

#### Declaration of competing interest

The authors declare that they have no known competing financial interests or personal relationships that could have appeared to influence the work reported in this paper.

## References

- [1] Zhu N, Zhang D, Wang W, Li X, Yang B, Song J, Zhao X, Huang B, Shi W, Lu R, Niu P. A novel coronavirus from patients with pneumonia in China. *N Engl J Med* 2019. 2020 Jan 24.
- [2] Wang C, Horby PW, Hayden FG, Gao GF. A novel coronavirus outbreak of global health concern. *Lancet* 2020 Feb 15;395(10223):470–3.
- [3] Zhou P, Yang XL, Wang XG, Hu B, Zhang L, Zhang W, Si HR, Zhu Y, Li B, Huang CL, Chen HD. A pneumonia outbreak associated with a new coronavirus of probable bat origin. *Nature* 2020 Mar;579(7798):270–3.
- [4] [Internet]. Who.int [cited 25 November 2020]. Available from: <https://www.who.int/docs/default-source/coronaviruse/situation-reports/20200315-sitrep-55-cov-id-19.pdf>; 2020.
- [5] Yusef D, Hayajneh W, Awad S, Momany S, Khassawneh B, Samrah S, Obeidat B, Raffee L, Al-Faouri I, Issa AB, Al Zamel H. Large outbreak of coronavirus disease among wedding attendees, Jordan. *Emerg Infect Dis* 2020 Sep;26(9):2165.
- [6] [Internet]. Who.int [cited 25 November 2020]. Available from: <https://www.who.int/docs/default-source/coronaviruse/situation-reports/20200410-sitrep-81-cov-id-19.pdf>; 2020.
- [7] [Internet]. Who.int [cited 25 November 2020]. Available from: [https://www.who.int/docs/default-source/coronaviruse/situation-reports/20201124\\_weekly\\_epi\\_update\\_15.pdf](https://www.who.int/docs/default-source/coronaviruse/situation-reports/20201124_weekly_epi_update_15.pdf); 2020.
- [8] Docherty AB, Harrison EM, Green CA, Hardwick HE, Pius R, Norman L, Holden KA, Read JM, Dondelinger F, Carson G, Merson L. Features of 20 133 UK patients in hospital with covid-19 using the ISARIC WHO Clinical Characterisation Protocol: prospective observational cohort study. *BMJ* 2020 May 22:369.
- [9] Khorana J, Singhavejsakul J, Ukarapol N, Laohapensang M, Siriwongmongkol J, Patumanond J. Prognostic indicators for failed nonsurgical reduction of intussusception. *Therapeut Clin Risk Manag* 2016;12:1231.
- [10] Cai X, Ma Y, Li S, Chen Y, Rong Z, Li W. Clinical characteristics of 5 COVID-19 cases with non-respiratory symptoms as the first manifestation in children. *Front Pediatr* 2020 May 12;8:258.
- [11] Cui X, Zhang T, Zheng J, Zhang J, Si P, Xu Y, Guo W, Liu Z, Li W, Ma J, Dong C. Children with coronavirus disease 2019 (COVID-19): a review of demographic, clinical, laboratory and imaging features in 2,597 pediatric patients. *J Med Virol* 2020 May 17.
- [12] Bines JE, Ivanoff B. Acute intussusception in infants and children: incidence, clinical presentation, and management: a global perspective. *World Health Organization*; 2002.
- [13] Moazzam Z, Salim A, Ashraf A, Jehan F, Arshad M. Intussusception in an infant as a manifestation of COVID-19. *J Pediatr Surg Case Rep* 2020 Aug 1;59:101533.
- [14] Bazuaye-Ekwuyasi EA, Camacho AC, Rios FS, Torck A, Choi WJ, Aigbivbalu EE, Mehdi MQ, Shelton KJ, Radhakrishnan GL, Radhakrishnan RS, Swischuk LE. Intussusception in a child with COVID-19 in the USA. *Emerg Radiol* 2020 Oct 6: 1–4.
- [15] Martínez-Castaño I, Calabuig-Barbero E, González-Piñera J, López-Ayala JM. COVID-19 infection is a diagnostic challenge in infants with ileocecal intussusception. *Pediatr Emerg Care* 2020 Jun 1;36(6):e368.
- [16] Doi O, Aoyama K, Hutson JM. Twenty-one cases of small bowel intussusception: the pathophysiology of idiopathic intussusception and the concept of benign small bowel intussusception. *Pediatr Surg Int* 2004 Feb 1;20(2):140–3.
- [17] Okimoto S, Hyodo S, Yamamoto M, Nakamura K, Kobayashi M. Association of viral isolates from stool samples with intussusception in children. *Int J Infect Dis* 2011 Sep 1;15(9):e641–5.
- [18] Bines JE, Liem NT, Justice FA, Son TN, Kirkwood CD, De Campo M, Barnett P, Bishop RF, Robins-Browne R, Carlin JB, Intussusception Study Group. Risk factors for intussusception in infants in Vietnam and Australia: adenovirus implicated, but not rotavirus. *J Pediatr* 2006 Oct 1;149(4):452–60.
- [19] Cera SM. Intestinal intussusception. *Clin Colon Rectal Surg* 2008;21(2):106.
- [20] Almeida JF Md, Chehter EZ. COVID-19 and the gastrointestinal tract: what do we already know? *Einstein*, vol. 18; 2020 (São Paulo).
- [21] Ding S, Liang TJ. Is SARS-CoV-2 also an enteric pathogen with potential Fecal-Oral transmission: a COVID-19 virological and clinical review. *Gastroenterology* 2020 Apr 27.
- [22] Xiao F, Tang M, Zheng X, Liu Y, Li X, Shan H. Evidence for gastrointestinal infection of SARS-CoV-2. *Gastroenterology* 2020;158(6):1831–3. e1833.
- [23] Hashimoto T, Perlot T, Rehman A, Trichereau J, Ishiguro H, Paolino M, Lipinski S. ACE2 links amino acid malnutrition to microbial ecology and intestinal inflammation. *Nature* 2012;487(7408):477–81.
- [24] Xu Y, Li X, Zhu B, Liang H, Fang C, Gong Y, Shen J. Characteristics of pediatric SARS-CoV-2 infection and potential evidence for persistent fecal viral shedding. *Nat Med* 2020;26(4):502–5.
- [25] Gu J, Han B, Wang J. COVID-19: gastrointestinal manifestations and potential fecal–oral transmission. *Gastroenterology* 2020;158(6):1518–9.
- [26] Samanta J, Dhar J, Khaliq A, Kochhar R. 2019 novel coronavirus infection: gastrointestinal manifestations. *J Dig Endosc* 2020;11(1):13.
- [27] Montgomery EA, Popek EJ. Intussusception, adenovirus, and children: a brief reaffirmation. *Hum Pathol* 1994;25(2):169–74.
- [28] Konno T, Suzuki H, Kutsuzawa T, Imai A, Katsushima N, Sakamoto M, Adachi M. Human rotavirus infection in infants and young children with intussusception. *J Med Virol* 1978;2(3):265–9.
- [29] Evermann J, Abbott J, Han S. Canine coronavirus-associated puppy mortality without evidence of concurrent canine parvovirus infection. *J Vet Diagn Invest* 2005;17(6):610–4.
- [30] Faez Khalaf M, Ali Abdulbaqi Ali Ismael M, Baghdadi M. Clinical diagnosis of the first cases of extrapulmonary (GIT) COVID-19 in Thi-Qar, south of Iraq. *Sys Rev Pharm* 2020;11(12):1712–6.
- [31] Giovanni JE, Hrapcak S, Melgar M, Godfred-Cato S. Global reports of intussusception in infants with SARS-CoV-2 infection. *Pediatr Infect Dis J* 2020;40(1):e35.
- [32] Willetts I, Kite P, Barclay G, Banks R, Rumley A, Allgar V, Stringer M. Endotoxin, cytokines and lipid peroxides in children with intussusception. *Br J Surg* 2001;88(6):878–83.